

Strategy of bone metastases treatment in patients with impending cord compression or vertebral fractures: a pilot study.



*N.Rasulova, V.Krylov, V. Lyubshin, Kyeong Hwan Kim, F.Djalalov,
L. Nazirova, D.Arybzhanov (Uzbekistan, South Korea, Kazakhstan)*

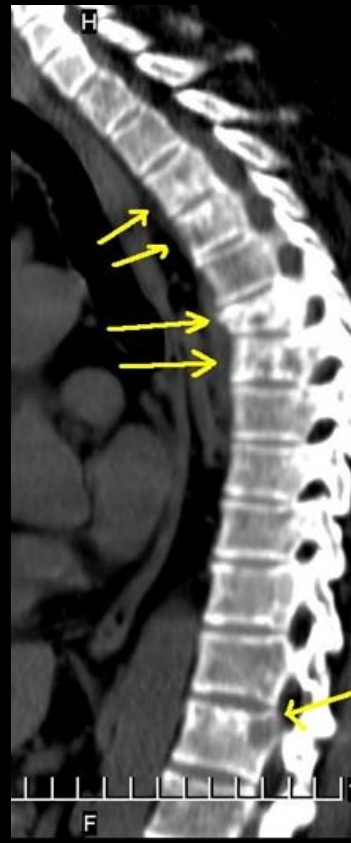
Impending cord compression and vertebral fractures are considered as contraindications for radionuclide bone therapy

However, most of the patients with widespread bone metastases already have weakened vertebral segments that may be broken.

Local field external-beam radiotherapy

Percutaneous vertebroplasty should be considered to improve the patient's quality of life

to enable suitable treatment, including radionuclide bone therapy.



Radiotherapy

- Highly effective for individual bony metastatic lesions
- Remains the standard of care for patients with localized bone pain but
- no impending risk of fracture .

While it is **effective at reducing tumor volume**, it is not helpful to prevent pathologic fracture **because it does not strengthen the anterior support of vertebral body.**



Vertebral metastases are worsening the quality of life

- But the treatment is still controversial
- Advantages of bone palliation by radionuclide therapy include the ability to simultaneously treat multiple sites of disease

Unfortunately, impending cord compression and vertebral fractures are considered as contraindications for radionuclide bone therapy.



Therefore, stabilizing procedure, such as percutaneous vertebroplasty, should be proceeded to enable radionuclide bone therapy



Objective: to create a strategy for an effective treatment of bone metastases in patients with widespread bone metastases and intolerable pain, associated with impending cord compression or vertebral fractures.

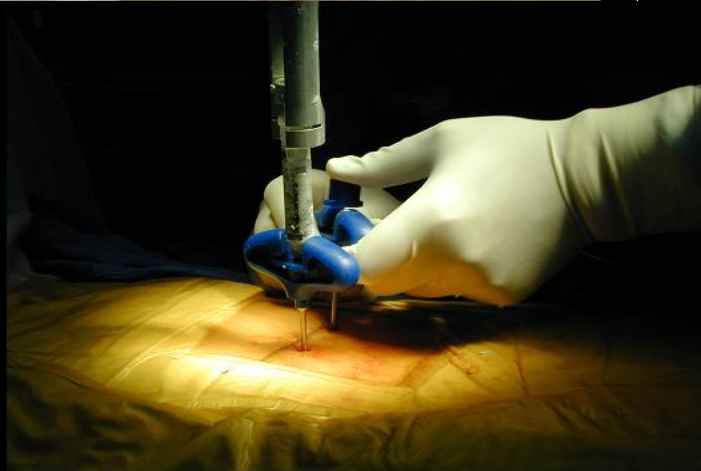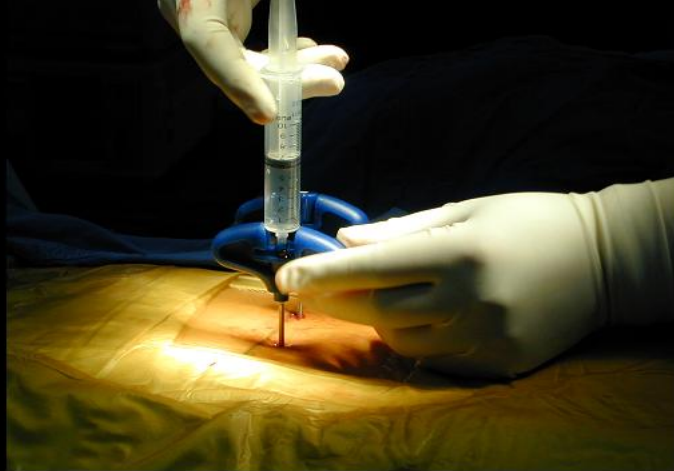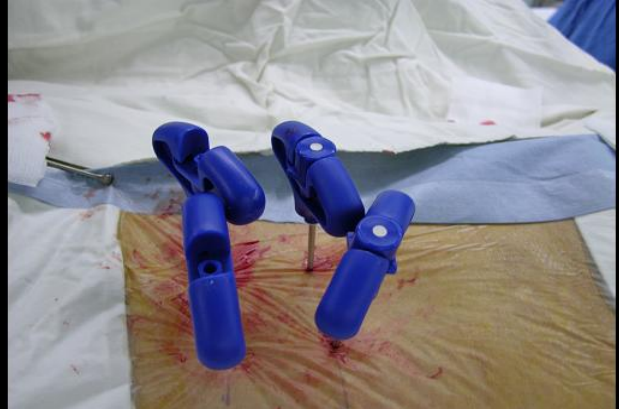


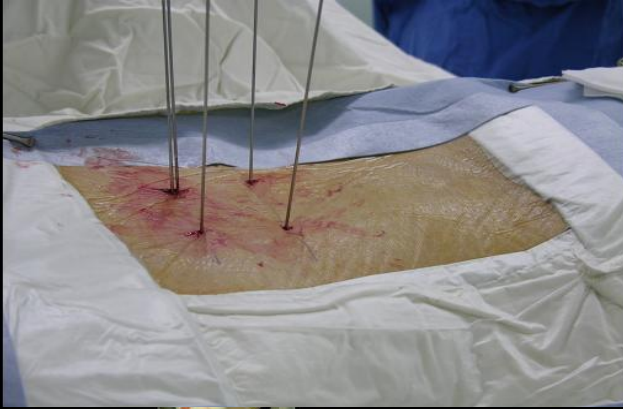Material and methods: 11 patients (5 female and 6 male, aged 32-62, mean age $53,8 \pm 2,7$) with multiple skeletal metastases from prostatic, breast or lung carcinoma

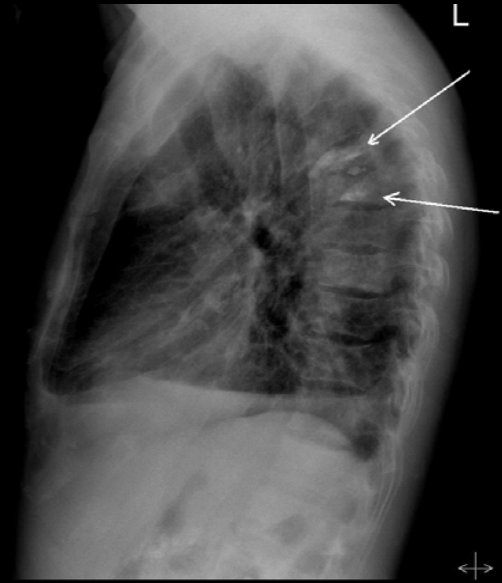
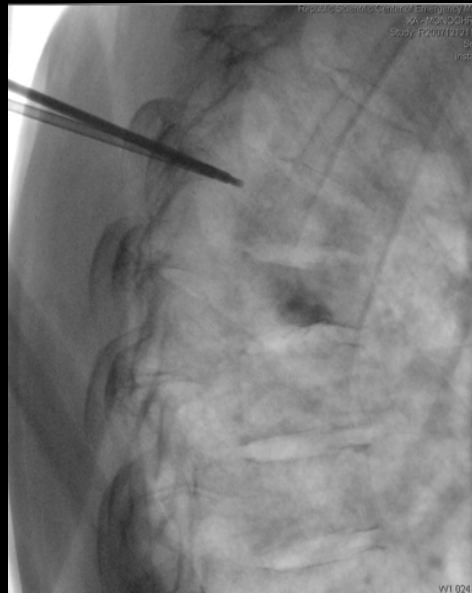
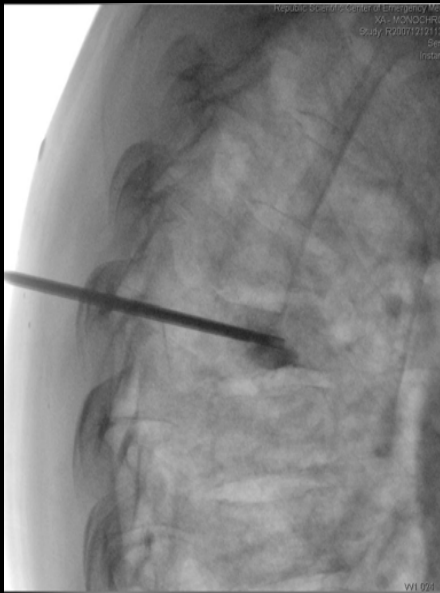
Their mean objective pain score according to 10 score system was $8,64 \pm 0,15$ (range 8-9) and the mean number of levels with impending cord compression or vertebral fracture was $2,64 \pm 0,34$ (range 1-4).

Prostatic carcinoma	Breast carcinoma	Lung carcinoma
3	3	5

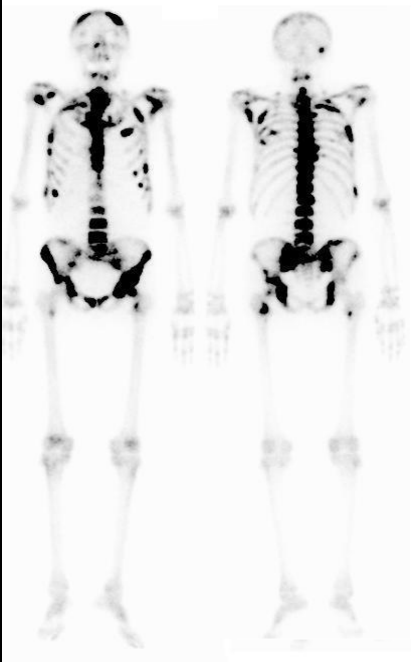
All patients underwent vertebroplasty by percutaneous injection of Polymethyl metacrylate into vertebral body



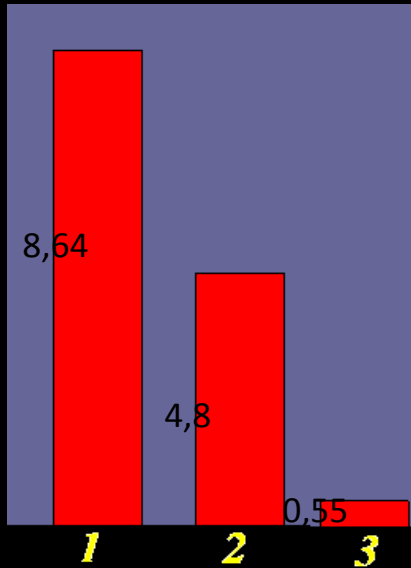
Percutaneous trans-pedicular injection of bone cement into the vertebral body



3-7 days after VP all patients received Sm-153 EDTMP therapy. Sm-153 EDTMP was administered at the standard bone palliation dose of 37 MBq/kg body weight.



Pain score (0-9)



Results :



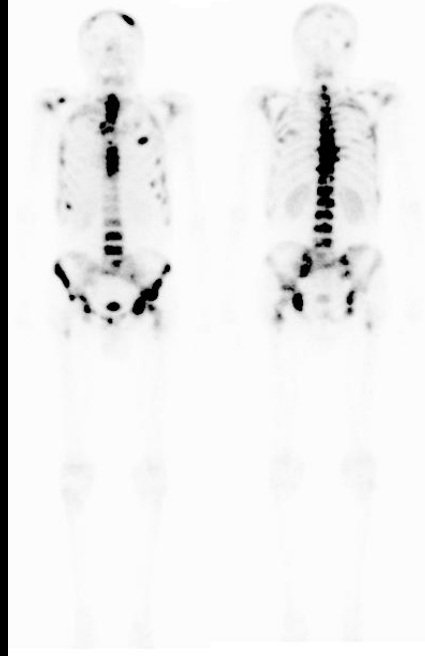
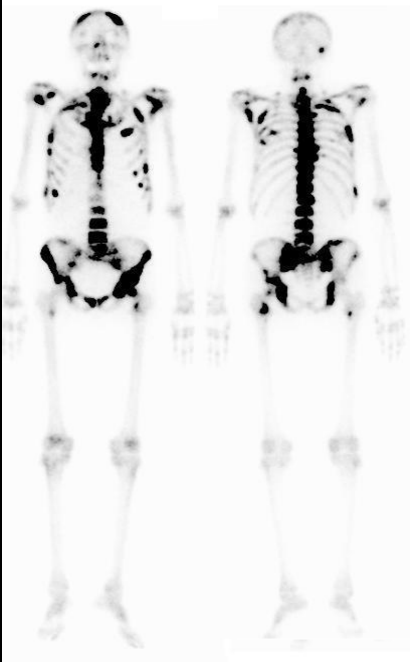
1. Before treatment
2. After vertebroplasty pain relief occurred within the first 12 hours (mean $4,8 \pm 1,2$; range 0,5-12 hrs)
3. After Sm-153 EDTMP treatment pain relief occurred in $3,91 \pm 0,39$ days (range 2-6 days)

WB bone scan



Initially

after 6 months



Conclusion:



Conclusion: spinal stabilization using vertebroplasty in patients with wide spread bone metastases and impending cord compression is an effective way to decrease disability with pain and to facilitate subsequent systemic palliation of painful skeletal metastases by administration of Sm-153 EDTMP